

## **100. Peripheral MRA**

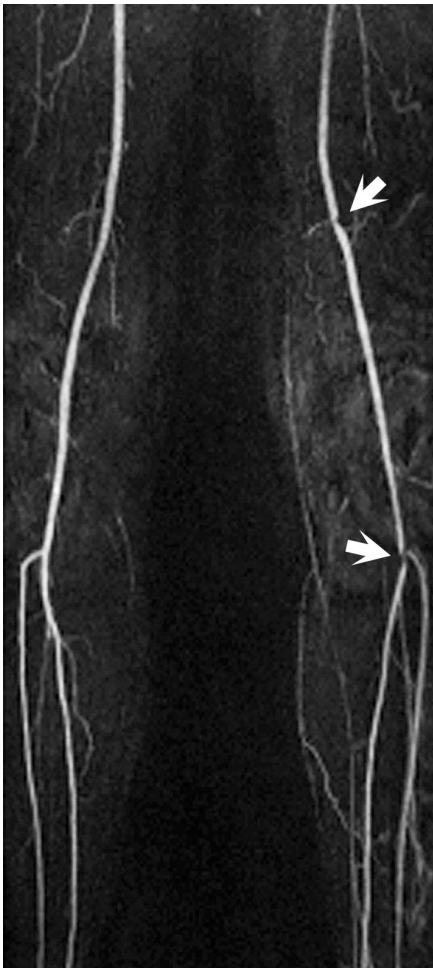
Magnetic resonance angiography (MRA), specifically contrast-enhanced MRA—the dominant clinical technique—offers a rapid, noninvasive evaluation of the peripheral vasculature with sensitivity and specificity for the detection and grading of stenoses near that of catheter angiography. The other major noninvasive technique, CT angiography, is limited in this application due to the lack of dynamic flow information and by its reduced accuracy in the presence of calcified plaque. CE-MRA sequences are typically obtained utilizing a heavily T1-weighted 3D spoiled gradient echo sequence. Contrast-enhanced (CE) MRA images are also acquired with a short echo time so as to reduce flow-related signal loss and susceptibility artifacts. Before the actual contrast injection, the same sequence later used for the contrast enhanced scan is typically acquired as a mask for subsequent subtractions.

Coordination of the arrival of the contrast bolus with image acquisition (i.e. bolus timing) is a critical consideration in CE MRA. Poor timing can result in a delay in acquiring the center of k-space leading to venous contamination or in scans acquired too early to achieve maximal obtainable intraarterial SI. Specifically, the center of k-space—the portion encoding data important for image contrast—should be sampled when arterial enhancement is at its peak. Several methods are employed for coordinating central k-space acquisition and bolus arrival. Bolus timing consists of acquiring a series of axial T1WI at the level of interest while a small test bolus (1-2 mL) is injected at the same rate as the actual bolus. This is used to calculate a circulation time so as to estimate the timing of bolus arrival during the actual examination. In certain applications, such as whole body MRA, more than one test bolus is needed. In distinction, with MR fluoroscopy, the full contrast dose is given, and serial coronal 2D images obtained until the bolus has arrived within the desired region, as determined through region of interest analysis by the system or manually by the technologist. Upon bolus arrival, the scan is then initiated. Using rapid, time-resolved MRA techniques such as TRICKS (time resolved imaging of contrast kinetics), TWIST (time-resolved angiography with interleaved stochastic trajectories), and TREAT (time-resolved echo-shared angiographic technique), the need for bolus timing is eliminated. These techniques undersample the periphery of k-space, while repeatedly sampling the center of k-space, allowing acquisition of image contrast information at a high rate. Due to the subsequent data acquisition at a high frame rate both arterial and venous phase images are acquired. This is especially useful in eliminating problems stemming from venous overlay in patients with altered hemodynamics, for example with collateral flow.

To optimize bolus timing and thus image contrast with respect to the total area of anatomic

coverage, several different techniques can be used. For peripheral MRA with the step-by-step approach, coronal images are typically obtained at three to four different stations (meaning the technologist must plan 3 to 4 different FOVs) so as to fully visualize all vessel stations from the diaphragm to the distal calves. Automated table positioning is then used to track the bolus and image the region of interest. For the purposes of avoiding venous contamination in the calves, this region can be scanned first utilizing a centric k-space acquisition strategy with the other evaluated FOVs (pelvis and thigh) scanned subsequently.

Effective CE-MRA techniques require both adequate temporal and spatial resolution, the latter in particular due to the small caliber vessels that must be visualized in the calf. The increased SNR afforded by imaging at 3 T as well as the prolonged T1-relaxivity of the background tissue at that field strength (leading to lower background SI on CE-MRA) enable reduced scan times for individual stations or alternatively higher spatial resolution when compared to 1.5 T.



Contrast enhanced MRA images are commonly presented for interpretation as maximum intensity projections (MIP), which due to acquisition of scans with near isotropic voxels (cube shaped voxels with equal length for each side) can be rotated into any desired plane, thus increasing the diagnostic accuracy of stenosis grading. Volume rendered images may also be employed. Source images should always be viewed alongside the MIP images, with examination of unsubtracted source images potentially improving vessel wall evaluation. A coronal MIP from a CE-MRA patient exam is illustrated in Fig. 100.1. Severe peripheral arterial occlusive disease of the runoff vasculature is present, with high-grade stenoses (arrows) of the left femoral and posterior tibial arteries present.

Fig. 100.1

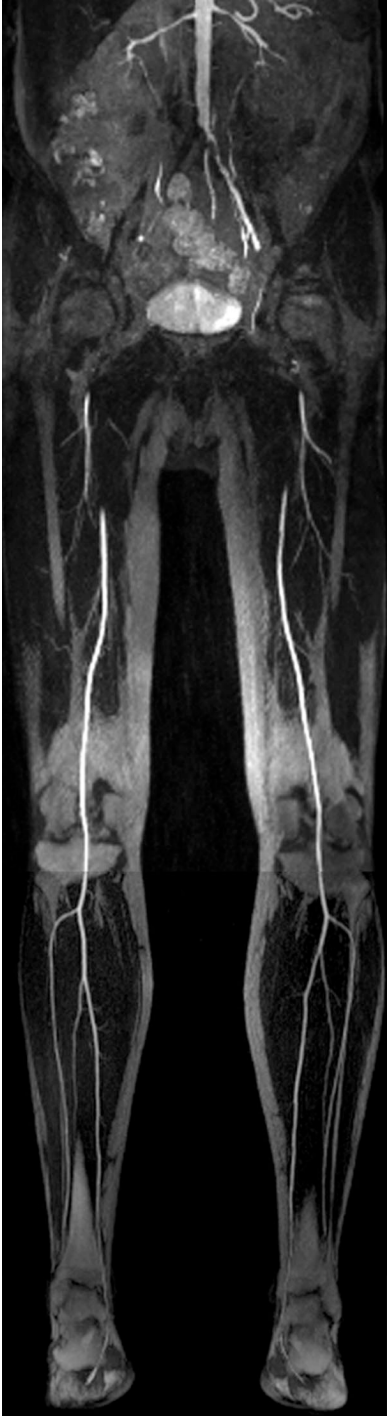

Fig. 100.2

Figures 100.2 and 100.3A (white arrow) are coronal CE-MRA MIPs illustrating complete occlusion of the right common iliac artery and high grade left iliac artery stenosis (in this patient with aortoiliac occlusive disease, also known as Leriche's syndrome). The length of stenoses is important to ascertain, as is the degree. With respect to the latter, assessment of the left external iliac artery is aided by visualization in multiple planes and obliquities (Fig. 100.3), including (B) sagittal and (C) axial images. The identification of collaterals—present extensively from the inferior mesenteric and epigastric arteries in this case (but not well illustrated in the figures presented)—vessel reconstitution, and patency of the distal vasculature are important findings to describe in evaluation of any vascular process. The length of a stenosis may further determine whether endovascular (if short segment) or open surgical repair is indicated.

Dynamic time-resolved MRA images in Figure 100.4 illustrate (A-C) early preferential filling of the left lower leg arterial system with poor and no flow demonstrated respectively in the right fibular (peroneal) and left posterior tibial arteries. Delayed images (D-F) exhibit venous filling—a finding often more prominent if there is a concomitant soft tissue infection. On these images, the mechanism for improved left-sided flow is obvious—an aortofemoropopliteal bypass (A, white arrows) to the left popliteal artery. Synthetic grafts themselves do not typically cause susceptibility artifact on MRA, although clips at

anastomotic sites may. Artifact from stainless steel may be severe and mimic a short segment occlusion. History and prior studies can aid in detecting such a false stenosis, a finding also identifiable by the sharp transition from the normal to stenotic vessel and lack of collateral blood flow. Nitinol stents and clips, however, typically do not produce severe artifacts.

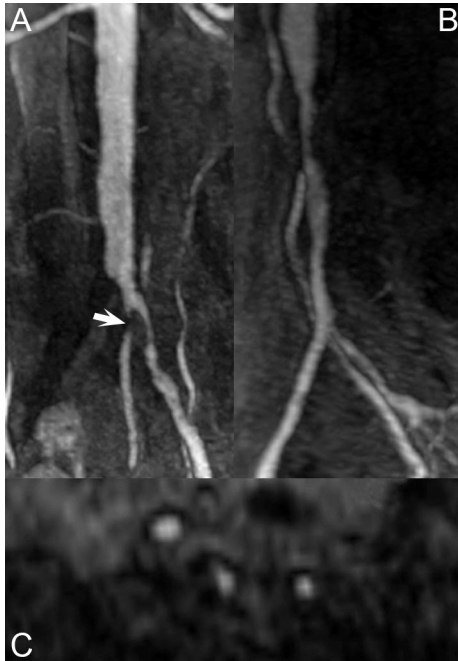


Fig. 100.3

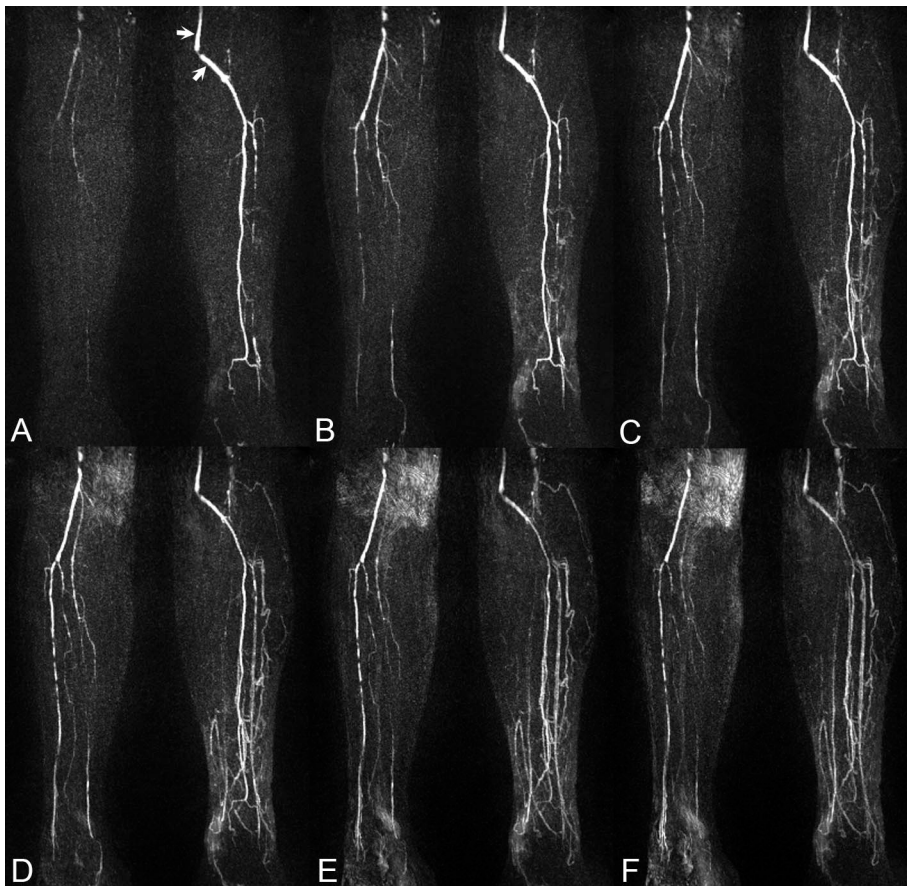


Fig 100.4