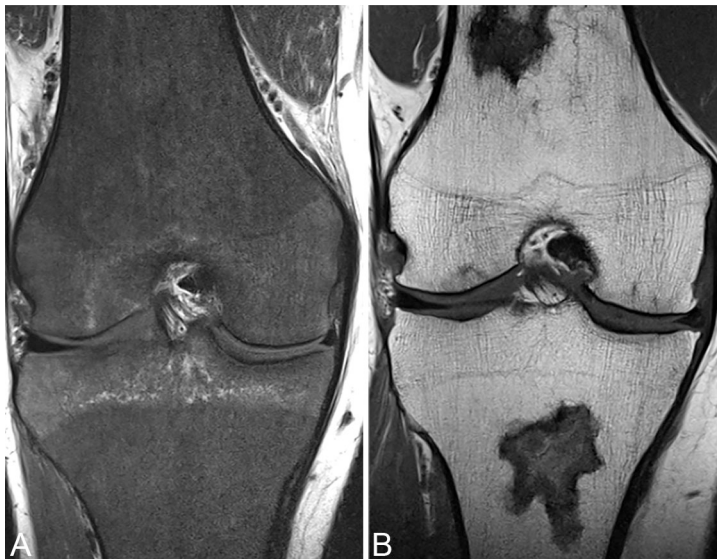

96. Diseases of Marrow

The rationale for the SI characteristics of normal adult bone marrow on SE and FSE T1 and T2WI has been described in previous chapters. Marrow SI on MR must also be interpreted in the context of a patient's age. At birth, hematologically active red marrow is widespread, its higher water content yielding a lower SI appearance than fatty marrow on T1WI.

Conversion to fatty marrow begins in the distal extremities, progressing proximally. Within 6 months of ossification, conversion begins in the extremities in epiphyses and apophyses, followed by diaphyseal conversion. Fatty replacement progresses proximally, ending in complete replacement within the appendicular skeleton and a predominance of yellow over red marrow in the axial skeleton.

Diffuse reconversion of yellow to red marrow may occur in pathologic conditions and normally in some individuals. The latter is erythropoietin-mediated and often present in endurance athletes, heavy smokers, obesity and diabetes. Reconversion typically proceeds from the axial skeleton, where some residual hematopoietic marrow normally remains, to the appendicular system.



Pathologic conditions leading to marrow hypointensity on T1WI include disorders leading to proliferation of cell line precursors such as leukemia, multiple myeloma, or polycythemia vera. The latter may progress to myelofibrosis, which appears as hypointensity on both T1 and T2WI. Use of

Fig. 96.1

erythropoietin and granulocyte stimulating chemotherapeutic agents may result in a similar appearance. The most common cause of hematogenous marrow reconversion is chronic anemia such as thalassemia or sickle cell. A case of the latter is illustrated in Figure 96.1A. The normal high SI marrow of the femur and tibia demonstrate diffuse hypointensity on T1WI, correlating with proliferation of hematopoietic marrow in response to the associated anemia. In the setting of multiple blood transfusions (transfusion hemosiderosis),

susceptibility effects from deposited iron lead to markedly low SI on FSE and GRE T2WI. Bone infarction is a possible sequelae of sickle cell disease, presenting in the acute phase with focal hypointensity on T1WI. Other factors may lead to bone infarction, synonymous with AVN discussed in previous chapters, including corticosteroid use, alcoholism, and collagen vascular disease. The patient in Figure 96.1B was on long-term steroid therapy for asthma: T1WI demonstrate focal areas of linear hypointensity outlining more moderate low SI regions within the distal femur and proximal tibia. The hypointense outline correlates with sclerosis and is characteristic for a chronic bone infarct as is the double line sign on T2WI whereby a hyperintense line is seen just within the hypointense sclerotic outline, correlating with granulation tissue. The signal intensity of bone infarctions on T1WI is variable in appearance, largely influenced by chronicity (for example low SI with edema acutely and high SI with fatty replacement chronically).

The spectrum of MR appearances for multiple myeloma has been described in previous chapters (normal to multifocal lesions to diffuse abnormal SI). Of note, multifocal hypointensity on T1WI may also be seen in monoclonal gammopathy of undetermined significance, while diffuse marrow replacement is more typical of myeloma. If inapparent on MR, myeloma is associated with a more delayed progression.

Following chemotherapy for myeloma, resolution of lesion enhancement or confinement of enhancement to a peripheral distribution is a marker of therapeutic response, as is the transformation of a diffuse pattern of involvement into a focal or variegated pattern. Focal areas of T1 hypointensity may also, and commonly, represent metastatic disease. Metastatic lesions typically also enhance, although this may be subtle unless the post-contrast scan is performed with fat suppression. Restricted diffusion (low ADCs) are characteristic as well for bony metastases.

Osteomyelitis is an additional cause of marrow edema. MR offers superior sensitivity, better sinus tract delineation, and improved detection of associated abscesses - in addition to allowing for operative planning, when compared to radionuclide bone scans. Typical findings on MR are illustrated in Figure 96.2. Extensive, confluent low and high SI on (A) T1 and (B) FS T2WI, respectively, involves the distal femur. Surrounding myositis and fasciitis are also present. (C) CE FS T1WI demonstrates the presence of a posterior subperiosteal abscess with an enhancing rim surrounding a low SI fluid collection. The distal femur enhances as well. The large fluid collection makes such differential considerations as primary neoplasm or bony metastasis unlikely. An osteoid osteoma may evoke extensive edema that obscures detection of its hypointense central nidus on FS T2WI, but the adjacent extensive soft tissue involvement rules out such a lesion. The distinction between osteomyelitis, diabetic arthropathy, and neuropathic joints can be

difficult within the lower extremity as further discussed in Chapter 94.

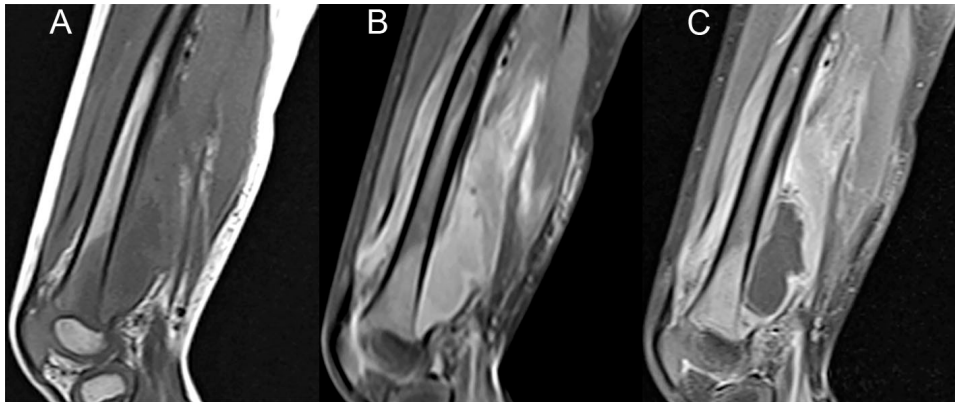


Fig. 96.2